

DERMASAVER CASE STUDY

CASE STUDY

WESBURY UNITED METHODIST COMMUNITY

■ BY AUTUMN SEELY FERRINGER, LPN, WCC

BACKGROUND HISTORY



PRIMARY CARE STAFF:
MIRANDA SLEE, CNA; SUSAN
JOHNSON, LPN; MELINDA CRAIG, LPN
FRONT: TAMMY SWAVEY, CNA

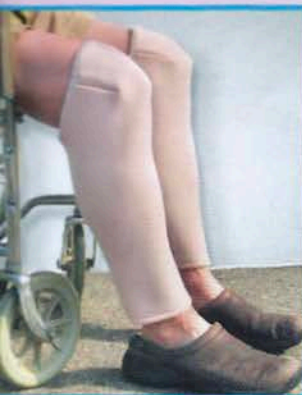A 93-year-old female admitted to the facility on May 7, 2007 with the following pertinent diagnoses; CVA, L hemi paresis, Aphasia, COPD, Cor Pulmonale, SVT, A fib, Tachy – Brady Syndrome, Pacemaker, HTN, Multiple Myeloma, Chronic Kidney Disease, Muscle Weakness, Ambulatory Dysfunction, Hip Replacement Status post, History of Steroid use and numerous additional diagnoses.

She takes the following medications; Nasonex spray, calcium carbonate, furosemide, aspirin, Protonix, metoprolol, docusate sodium, multi vitamin, paroxetine hcl, prednisone, theophylline, Xopenex,

Dulcolax, milk of magnesia, acetaminophen and Mylanta.

Due to her age, medical history and resulting medications, especially long standing steroid therapy, her skin is thin and fragile. She has hemosiderin staining to all 4 of her extremities from repeated trauma to her skin with minimal contact, as well as frequent skin tears. At times she will develop a bullae or hematoma that will ulcerate and require debridement. Healing is slowed due to the same reasons her skin is fragile. Prevention is key in the plan of care for this resident. Her personal goal on admission to our facility was to "make my legs like new". Upon admission we were challenged with skin tears to her lower extremities that were large and required debridement to remove eschar so we could work towards healing. While we succeeded in healing those areas we failed to keep her free of repeated trauma since the slightest bump results in a complicated skin injury.

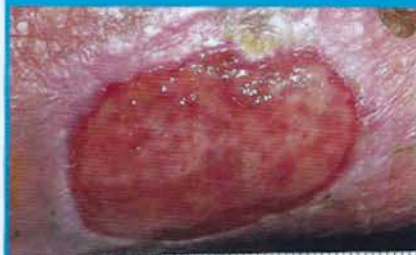
Once we saw the DermaSaver leg protectors we wanted to try them in order for her to reach her goal. When wearing the DermaSaver product, her legs were protected and provided an opportunity to heal without any recurrent injury to them. Her legs also looked smooth and toned. During the time she has worn the DermaSaver Shin-Knee tubes the only injury she had to her one lower extremity was on her lateral thigh beyond the area covered by the DermaSaver product.



DERMASAVER SHIN-KNEE TUBE

66419

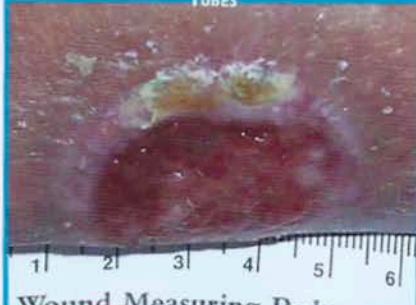BEFORE USING DERMASAVER SHIN-KNEE TUBES



10/1/07

RIGHT SHIN

AFTER 15 DAYS USING DERMASAVER SHIN-KNEE TUBES

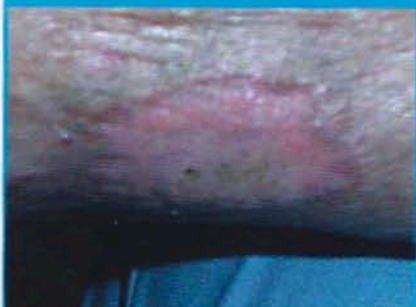

Wound Measuring Ruler

10/16/07

RIGHT SHIN

AFTER USING DERMASAVER SHIN-KNEE TUBES



11/08/07

RIGHT SHIN